

Artificial hip replacement

Hui Wang (individual)

NEU ID: 000524925

2011.11.29

Abstract

Hip replacement is a surgical procedure in which the hip joint is replaced by a prosthetic implant. Hip replacement surgery can be performed as a total replacement or a hemi (half) replacement. This can relieve pain, help hip joint work better, and improve walking and other movements. Now, hip replacement surgery is performed over 300,000 times each year in the U.S. to repair severe hip damage and has a very high success rate, and can offer an incredible quality of life improvement to some patients. During the surgery there are several different incisions, defined by their relation to the gluteus medius. The approaches are posterior, lateral, antero-lateral, anterior and greater trochanter osteotomy. Risks and complications in hip replacement are similar to those associated with all joint replacements. They can include dislocation, loosening, impingement, infection, osteolysis, metal sensitivity, nerve palsy, pain and death.

1. Introduction

The hip joint is located where the upper end of the femur meets the acetabulum. The femur, or thigh bone, looks like a long stem with a ball on the end. The acetabulum is a socket or cup-like structure in the pelvis, or hip bone. This "ball and socket" arrangement allows a wide range of motion, including sitting, standing, walking, and other daily activities. But as a person ages, the water content of the cartilage decreases as a result of a reduced proteoglycan content, thus causing the cartilage to be less resilient. That means the friction will increase and this can happen as breakdown products from the cartilage are released into the synovial space.^[1] (See the left hip of Figure 3). In general, mechanical stress on joints underlies all osteoarthritis, with many and varied sources of mechanical stress, including misalignments of bones caused by congenital or pathogenic causes; mechanical injury; overweight; loss of strength in muscles supporting joints; and impairment of peripheral nerves, leading to sudden or uncoordinated movements that overstress joints.^[3]

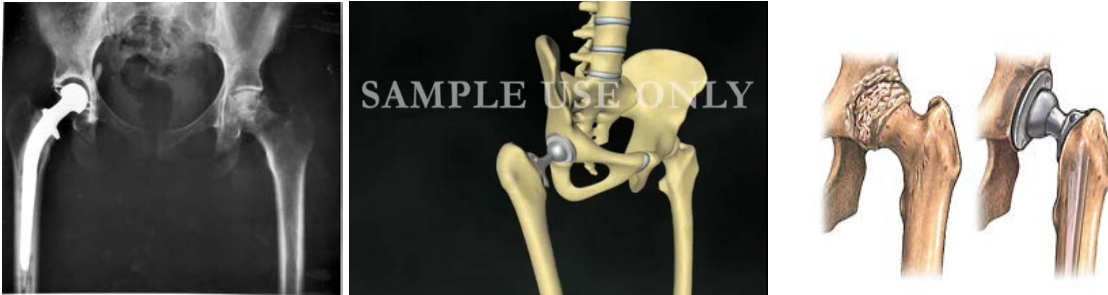

Figure 1, In this X-ray, the patient's right hip (left of image) has been replaced, with the ball of this ball-and-socket joint replaced by a metal head that is set in the thighbone or femur and the socket replaced by a white plastic cup (clear in this X-ray). Figure 2 & 3 are analog pictures.

2. Surgery profile

Now, the artificial hip replacement is the best way to heal osteoarthritis. Hip replacement is a surgical procedure in which the hip joint is replaced by a prosthetic implant. Hip prostheses consist of a ball component, made of metal or ceramic, and a socket, which has an insert or liner made of plastic, ceramic or metal.^[4] Hip replacement surgery can be performed as a total replacement or a hemi (half) replacement. Such joint replacement orthopaedic surgery generally is conducted to relieve arthritis pain or fix severe physical joint damage as part of hip fracture treatment. A total hip replacement (total hip arthroplasty) consists of replacing both the acetabulum and the femoral head while hemi-arthroplasty generally only replaces the femoral head. Hip replacement is currently the most common orthopaedic operation. Table 1 and 2 are from a study which to investigate patient-reported outcome in terms of satisfaction in two study groups that had undergone hip resurfacing arthroplasty (HRA) or total hip replacement (THR). The procedure consists of placing a hollow, mushroom-shaped metal cap over the femoral head while a matching metal cup is placed in the acetabulum (pelvis socket).^[4] They show that both groups (HRA and THR) reported high levels of overall satisfaction, with 97% and 93% being very satisfied or satisfied.

Figure 4

TABLE 1		
Characteristics of total hip replacement and hip resurfacing arthroplasty (n = 84).		
	Total hip replacement	Hip resurfacing arthroplasty
Women, %	33	37
Men, %	67	63
Age, years, mean	61	55
Idiopathic arthritis, n	32	40
Secondary arthrosis based on mild dysplasia, n	4	8

Figure 5

TABLE 2										
Patient satisfaction (n = 84) after total hip replacement and hip resurfacing arthroplasty as percentages.	Question	Total hip replacement				Hip resurfacing arthroplasty				p value
		very satisfied	satisfied	un-satisfied	very un-satisfied	very satisfied	satisfied	un-satisfied	very un-satisfied	
	Overall satisfaction: How satisfied are you with your artificial hip in terms of pain you currently experience?	58	39	3	–	70	23	6	–	0.27
	<i>How satisfied are you with your artificial hip in terms of</i>									
	Sitting?	67	33	–	–	66	32	2	–	0.68
	Standing?	60	37	3	–	67	29	4	–	0.73
	Getting in and out of bed?	69	29	3	–	77	23	–	–	0.40
	Climbing stairs?	56	33	8	3	56	40	4	3	0.54
	Walking longer distances (more than 30 min. without a break)?	60	23	14	3	51	36	6	3	0.35
	Participating in sports? ^a	26	58	11	5	50	37	10	5	0.41
	Having sexual intercourse?	52	45	3	–	55	41	5	–	0.92
	Your social life?	69	31	–	–	72	23	4	–	0.37
	Performing your job? ^b	62	38	–	–	66	32	–	–	0.69

a) A total of 15 total hip replacement patients and 14 hip resurfacing arthroplasty patients indicated that they did not practice any sports – these patients were excluded from this analysis.

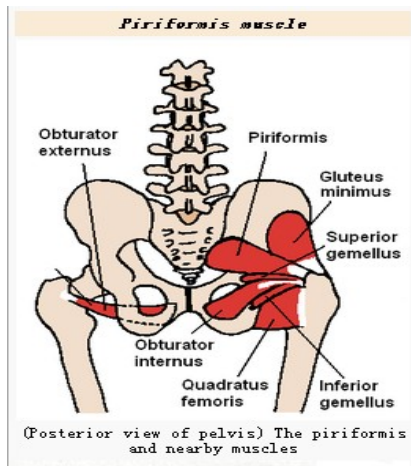
b) A total of 15 total hip replacement patients and 11 hip resurfacing arthroplasty patients said that they were not active in the labour market – these patients are excluded in this analysis.

3. Hip replacement techniques

There are several different incisions, defined by their relation to the gluteus medius. The approaches are posterior, lateral,^[5] antero-lateral, anterior and greater trochanter osteotomy. There is no compelling evidence in the literature for any particular approach, but consensus of professional opinion favors either modified anterolateral or posterior approach.

The posterior approach accesses the joint and capsule through the back, taking piriformis muscle and the short external rotators off the femur. The piriformis is a

muscle in the gluteal region of the lower limb and is part of the lateral rotators of the hip, along with the quadratus femoris, gemellus inferior, gemellus superior,



obturator externus, and obturator internus. The piriformis laterally rotates the extended thigh and abducts the flexed thigh. Abduction of the flexed thigh is important in the action of walking because it shifts the body weight to the opposite side of the foot being lifted, which keeps us from falling. This approach gives excellent access to the acetabulum and femur and preserves the hip abductors and thus minimizes the risk of abductor dysfunction post operatively. It has the advantage of becoming a more extensile approach if needed. Critics cite a higher dislocation rate, although repair of

Figure 6, (Posterior view of pelvis) The piriformis and nearby muscle

the capsule, piriformis and the short external rotators along with use of modern large diameter head balls negates this risk.

The lateral approach is also commonly used for hip replacement. A direct lateral approach to the hip is described which allows adequate access for orientation of the implant, for the insertion of the cement and for the correction of discrepancy in leg length. An anatomical observation was made that the gluteus medius muscle is inserted into the greater trochanter by a tendon and that the axis of the shaft of the femur lies to the main bulk of the muscle which was left undisturbed. Figure 7 shows the incision of the tendon of the gluteus medius leaves a cuff of tendon attached to the greater trochanter to facilitate closure and early function. Figure 8, the neck of the femur can be divided with a Gigli saw since the axis of the neck and shaft of the femur are anterior to the apex of the trochanter and main mass of gluteus medius which is left undisturbed.

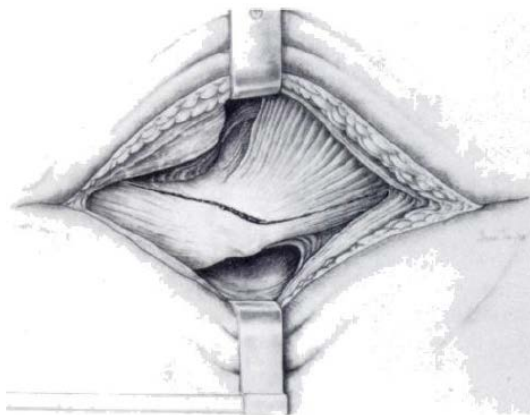


Figure 7

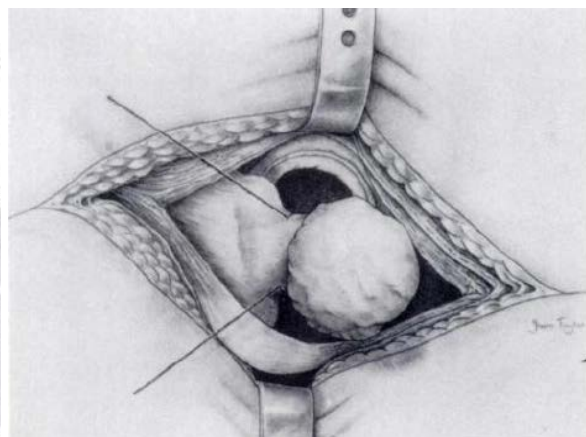


Figure 8

Figure 9, shows the closure of the joint after arthroplasty. Firm sutures are passed through the confluent ligament of bigelow and the tendon of the gluteus minimus. Figure 10, the closure of the gluteus medius tendon allows early mobilisation with weight-bearing.

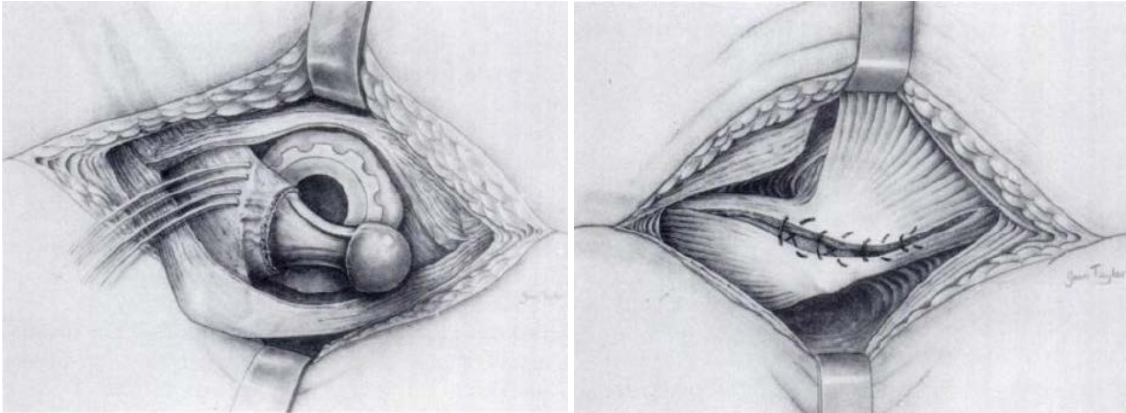


Figure 9

Figure 10

This approach requires elevation of the hip abductors (gluteus medius and gluteus minimus) in order to access the joint. The abductors may be lifted up by osteotomy of the greater trochanter and reapplying it afterwards using wires (as per Charnley), or may be divided at their tendinous portion, or through the functional tendon (as per Hardinge) and repaired using sutures.

The anterolateral approach develops the interval between the tensor fasciae latae and the gluteus medius. For the anterolateral approach, the oxygen concentration was found to be highly dependent upon the position of the leg, which was adjusted during surgery to provide exposure to the acetabulum and femoral head. Gross external rotation of the hip gave a significant decrease in oxygenation of the femoral head. Straightening the limb led to recovery in oxygen concentration, indicating that the blood supply was maintained. The oxygen concentration at the end of the procedure was not significantly different from that at the start. The anterolateral approach appears to produce less disruption to the blood flow in the femoral head-neck junction than the posterior approach for patients undergoing hip resurfacing. This may be reflected subsequently in a lower incidence of fracture of the femoral neck and avascular necrosis.^[11]

The anterior approach utilises an interval between the sartorius muscle and tensor fascia latae. Dr. Joel Matta has adapted this approach commonly used for pelvic fracture repair surgery in conjunction with a traction table for use when performing hip replacement. When used with older hip implant systems that had a small diameter head, dislocation rates were reduced compared to surgery performed through a posterior approach. With modern implant designs, dislocation rates are similar regardless of the approach and probably more a function of surgeon experience. There is a 10% rate of numbness in the thigh following this approach due to injury to the lateral femoral cutaneous nerve.

Another new hip replacement surgery called minimally-invasive technique. The main difference between the two procedures is the size of the incision. The small cuts are

thought to lessen blood loss, ease pain following surgery, shorten hospital stays, reduce scar appearance, and speed healing. However, it's important that the surgeon be highly skilled in this technique. Research has shown the outcomes with minimally-invasive approach may be worse than with standard hip replacement surgery if done by a doctor that is not very experienced with this technique. Surgeons using these approaches are advised to use intraoperative x-ray fluoroscopy or computer guidance systems also called Computer Assisted Surgery (CAS) which are available to guide the surgeon to provide enhanced accuracy. The most important component for CAS is the development of an accurate model of the patient. This can be conducted through a number of medical imaging technologies including CT, MRI, x-rays, ultrasound plus many more. For the generation of this model, the anatomical region to be operated has to be scanned and uploaded into the computer system. It is possible to employ a number of scanning methods, with the datasets combined through data fusion techniques. The final objective is the creation of a 3D dataset that reproduces the exact geometrical situation of the normal and pathological tissues and structures of that region. So, the hip replacement surgery will follow this procedure:

- Creating a virtual image of the patient
- Image analysis and processing
- Diagnostic
- Preoperative planning
- Surgical simulation
- Surgical navigation
- Surgical operation

4. Tribology of artificial hip joints

4.1 Materials and design of bearing surfaces

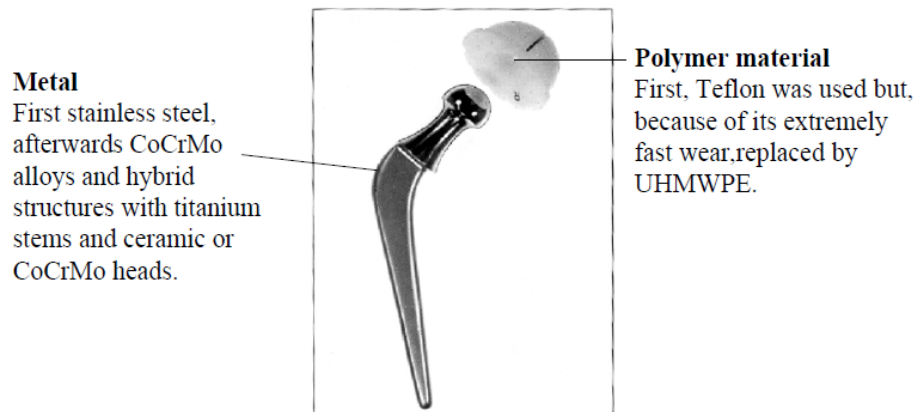
Currently, the alternatively bearing of hip implants to reduce wear including:



- a. crosslink polyethylene to metal total hip replacement
- b. metal to metal total hip replacement
- c. ceramic to ceramic total hip replacement

4.1.1 UHMWPE-metal total hip replacement


For the last 30 years, the (UHMWPE) ultra high molecular weight polyethylene has been coupled with a number of different hard materials for bearing surfaces in artificial joints. These include stainless steel (316S), titanium alloy (Ti 6Al 4V), cobalt chrome molybdenum alloy (Co 28Cr 6Mo) and aluminium oxide ceramic (alumina). The hard material is usually prepared with a smooth highly polished surface, in an attempt to minimize friction and wear of the softer polymer. In the hip joints the spherical femoral head articulates in a hemispherical UHMWPE socket. Use a polymer on metal couple so as to achieve low friction and low contact pressure.



Now we know the polymer has an ultimate tensile strength of approximately 25 MPa, but starts to deform plastically at stresses as low as 12 MPa. But the design and geometry of the bearing surfaces are important in order to control the contact stresses on the UHMWPE. A reduction of the contact stresses can be achieved by increasing the conformity and area of contact between the bearing surfaces. Metal-on-polymer hip replacements operate in the boundary lubrication regime, thus leading to the design guidance to reduce the femoral head diameter as much as is feasible to minimize frictional torque and volumetric wear. This explains why the gold-standard implant of this form from the past half-century had a diameter of only 22.225 mm (7/8 in).

4.1.2 Metal-metal total hip replacement

To use harder materials less sensitive to wear than UHMWPE, such as metal on metal or ceramic on ceramic couples. The basic tribological features of metal-on-metal total hip replacements (as shown in the following figure) have been reviewed to facilitate an understanding of the engineering science underpinning the renaissance of these hard-on-hard joints. Metal-on-metal implants can operate in the mild mixed lubrication regime in which much of the applied load is supported by elastohydrodynamic films. Correct tribological design leads to remarkably low steady state wear rates.




Promotion of the most effective elastohydrodynamic films calls for the largest possible head diameters and the smallest clearances that can reasonably be adopted, consistent with fine surface finishes, good sphericity and minimal structural elastic deformation of the cup on its foundations. This guidance, which is opposite in form to that developed for metal-on-polymer joints, is equally valid for solid (monolithic) metallic heads on metallic femoral stems and surface replacement femoral shells. Laboratory measurements of friction and wear in metal-on-metal joints have confirmed their potential to achieve a very mild form of mixed lubrication. The key lies in the generation of effective elastohydrodynamic lubricating films of adequate thickness compared with the composite roughness of the head and cup. The tribological requirements for contacting materials including:

- No blocking of joint by too strong interfacial adhesion
- High resistance against wear
- High resistance against scratching (high hardness)
- High resistance against fatigue and impacts (high toughness)

For example,


Materials for “low wear,, hip joints

CoCrMo alloys




$E = 200$
 $K = 20$
 $H = 350$

Al_2O_3



$E = 390$
 $K = 2 - 4$
 $H = 2000$

ZrO_2



$E = 200$
 $K = 6 - 9$
 $H = 1200$

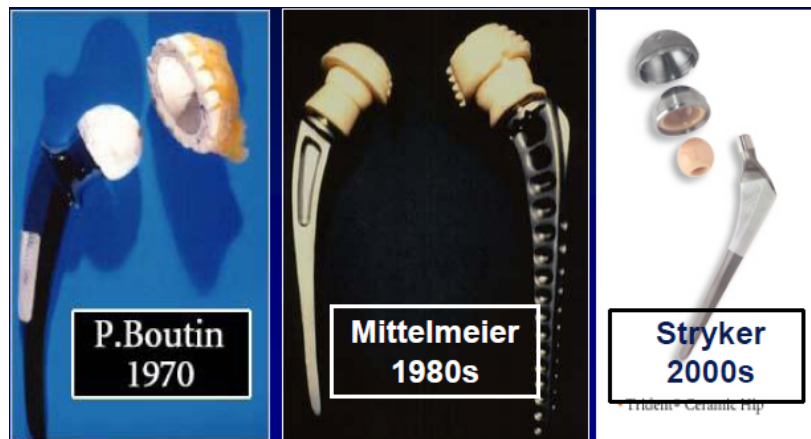E : Young's modulus [GPa]

K : Fracture toughness [MPa√m]

H : Vickers hardness [HV]

4.1.3 Ceramic to ceramic total hip replacement

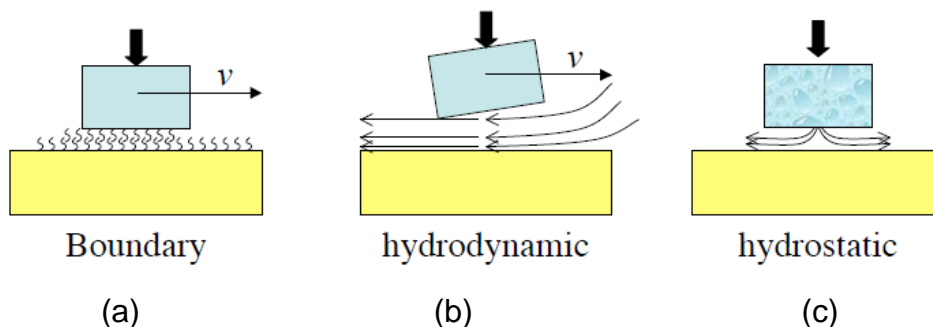
In the ceramic-on-ceramic hip replacement (as shown in the following figure) the articulating surfaces are made from aluminum oxide ceramic. Ceramic components are extremely wear resistant and have much smaller debris particles than the metal-on-polyethylene plastic articulation. The surfaces have a high wettability which also reduces friction in the joint. The FDA has approved for marketing ceramic hips offered by Wright Medical, Stryker Osteonics, and Encore Orthopedics. Other companies are expected to contract with the ceramics supplier for their own branded products in the near future.



4.2 Tribological contacts in hip joints

4.2.1 contact and lubrication of natural synovial joints

Synovial joints, such as those in the major joints of the body, possess excellent tribological properties, particularly in terms of high resistance to wear and low coefficients of friction. For many years, these joints have been considered a close analogy to engineering bearings. This comparison is even more remarkable when considering the very wide range of operating conditions under which synovial joints are required to operate, from high-speed sliding (e.g. when running) to short duration, high load, shock/transient events (jumping, trauma) to no motion at all (standing, sleeping), something that many of their engineering counterparts are not required to do.




Lubrication in synovial joints is a complex issue, and despite significant research, no definitive mechanism has been described. Instead, a combination of lubrication modes is thought to operate in the joint depending on the current prevailing operating conditions. Fluid film and boundary layer lubrication have both been shown to be important contributors under the right conditions. Other theories have been proposed, operating in the mixed regime, such as weeping lubrication, boosted lubrication, adaptive multimode lubrication, and biphasic lubrication. As shown in the above figure, (a) shows the boundary lubrication by adsorption of organic compounds of low shear strength; (b) shows the hydrodynamic lubrication by liquid film squeezed into the contact by motion; (c) shows the hydrostatic lubrication by a fluid film ejected from the cartilage when landing the joint.

4.2.2 Tribological evaluation of artificial hip joint

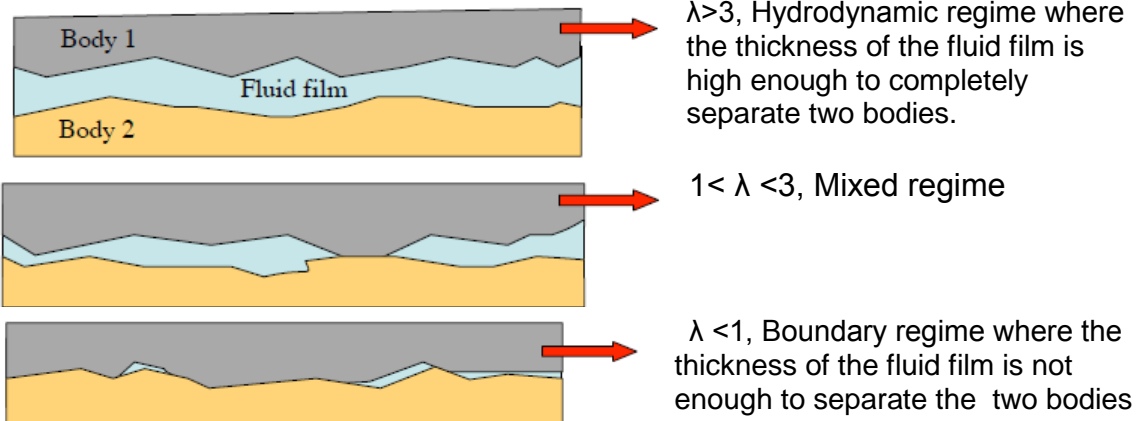
Unlike natural synovial joints, which are lubricated with a full fluid film lubrication mechanism, conventional artificial hip joints are lubricated with a mixed lubrication mechanism. Recently, however, a new generation of artificial hip joints employing compliant layers to mimic the compliance of articular cartilage in natural synovial joints have been developed to provide fluid film lubrication in these joints. While satisfactory lubrication can be achieved by employing soft layers, compliant thin layers are susceptible to the debonding between the soft layer and its stiffer substrate and long-term mechanical fatigue failure. Stress analyses for different designs of such joints are therefore important.

The coefficient determines the lubrication regime.

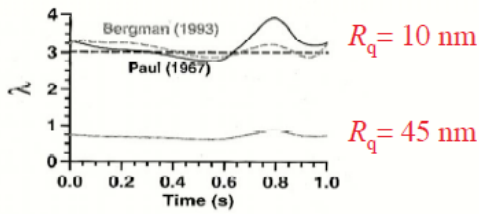
$$\lambda = \frac{h_{min}}{R_a}$$



Where, h_{min} is the average film thickness; and R_a is the composite surface roughness of two bearing surface.



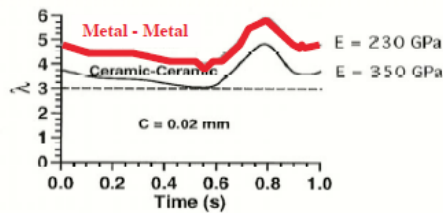
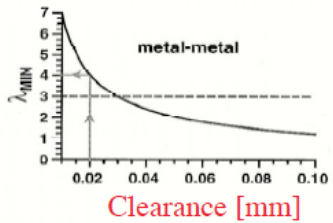
For example, hydrodynamic lubrication in hip joints, λ values calculated for typical load and velocity transients during gait, $\lambda > 3$.



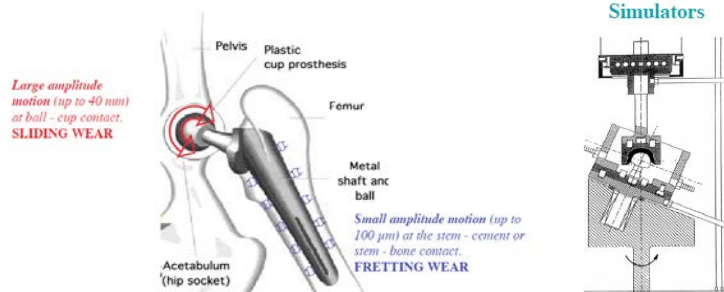Assume 1 step/ second

Head diameter $D=28\text{mm}$
 Clearance $C=0.033\text{mm}$
 Roughness $R_q=10\text{nm}$
 Viscosity $\eta=1.5\text{mPa s}$
 Young's modulus $E=230\text{GPa}$
 Poisson's coefficient $=0.3$

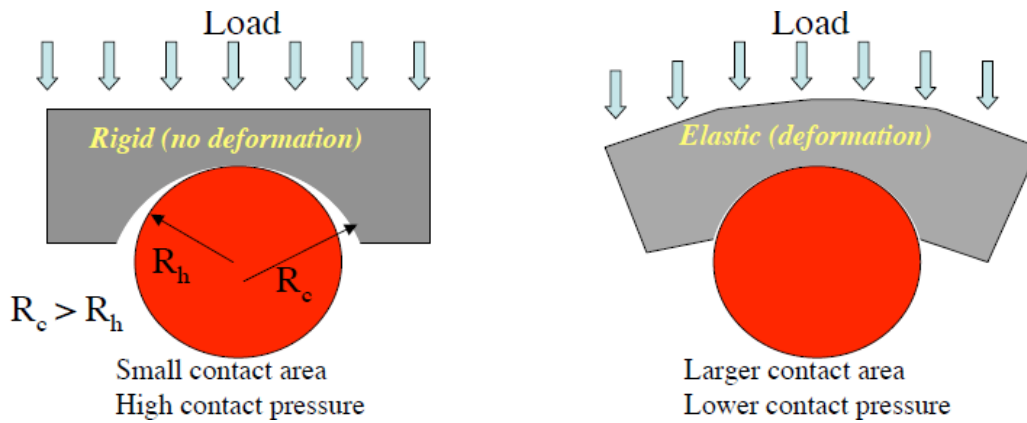
Then, we will get the result in the left figure.



The pressures on human articular cartilage have been measured in vivo. An instrumented femoral head prosthesis that telemeters interarticular pressure at 10 discrete locations 253 times per second was implanted in apposition to natural acetabular cartilage. Data were acquired during surgery, recovery, rehabilitation, and normal activity, for longer than 1 year after surgery. Pressure magnitudes were synchronized with body-segment kinematic data and foot-floor force measurements so as to locate transduced pressure areas on the natural acetabulum and correlate movement kinematics and dynamics with local cartilage pressures. The data reveal very high local (up to 18 MPa) and nonuniform pressures, with abrupt spatial and temporal gradients, that correlate well both in magnitude and distribution with in vitro data and computer simulations of synovial joint mechanics.



Contact pressure:



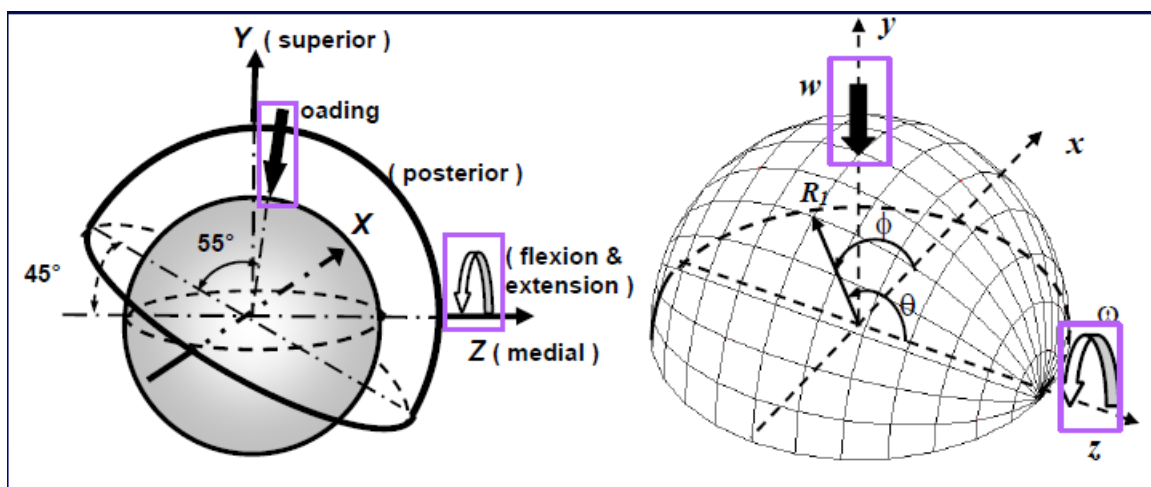
For example,

Example for $R_h = 15 \text{ mm}$, $R_c = 15.05$, 3000 N load

Contact	Bone- cartilage	2	MPa Contact pressure
	316L - UHMWPE	2	
	CoCr - UHMWPE	2	
	Bone - Bone	23	
	CoCr - CoCr	119	
	Al_2O_3 - Al_2O_3	157	

(calculated using Hertz theory for elastic deformation)

Elastic-hydrodynamic lubrication analysis,



Reynolds Equation: p

$$\sin\theta \frac{\partial}{\partial\theta} (h^3 \sin\theta \frac{\partial p}{\partial\theta}) + \frac{\partial}{\partial\varphi} (h^3 \frac{\partial p}{\partial\varphi})$$

$$= 6\mu R_2^2 \sin\theta \left[\begin{array}{l} (-\omega_x \sin\varphi + \omega_y \cos\varphi) \sin\theta \frac{\partial h}{\partial\theta} \\ + (-\omega_x \cos\varphi \cos\theta - \omega_y \sin\varphi \cos\theta + \omega_z \sin\theta) \frac{\partial h}{\partial\varphi} \end{array} \right] + 12\mu R_2^2 \sin^2\theta \frac{\partial h}{\partial t}$$

- Finite difference method
- Newton-Raphson method (Jagatia and Jin 2001)
- Multigrid (Gao et al 2006)

Film Thickness Equation, h

$$h(\varphi, \theta, t) = C \left[1 - \varepsilon_x(t) \sin\theta \cos\varphi - \varepsilon_y(t) \sin\theta \sin\varphi - \varepsilon_z(t) \cos\theta \right] + \delta(\varphi, \theta, t)$$

- Elastic Deformation, δ
- Finite element method to determine influence coefficients
- Fast Fourier transform (Wang and Jin, 2004)

$$\text{FFT}[\delta_{ij}(\varphi, \lambda)]_{2m \times 2n} = \text{FFT}[p_{ij}(\varphi, \lambda) \sin(\lambda_j)]_{2m \times 2n} \bullet \text{FFT}[S_{ij}(\varphi, \lambda; \lambda_m)]_{2m \times 2n}$$

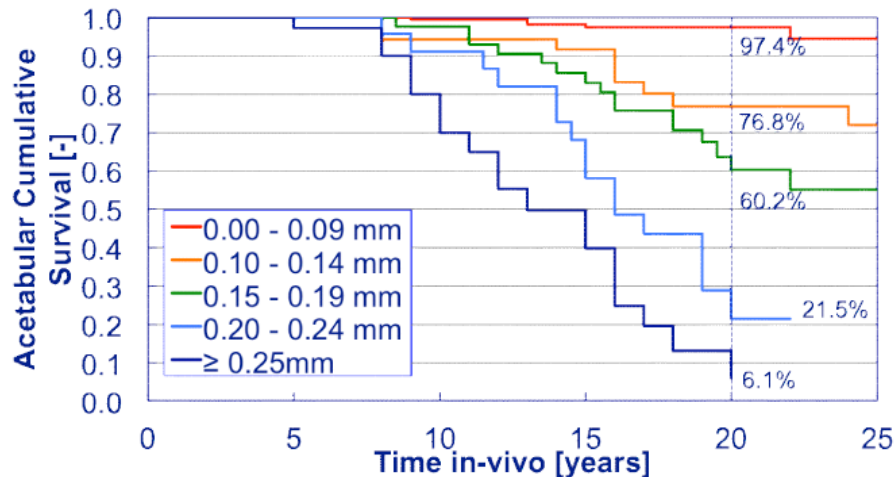
- Multilevel integration

Finally, we can get some results from this evaluation.

In-vivo wear rates

Cup	Head	Linear wear mm/year	
Polyethylene	Stainless Steel	0.1-0.3	(Polyethylene)
Polyethylene	CoCrMo-Metal	0.1-0.3	(Polyethylene)
Polyethylene	Al ₂ O ₃ -Ceramic	0.05-0.15	(Polyethylene)
CoCrMo-Metal	CoCrMo-Metal	0.003-0.01	(CoCrMo)
Al ₂ O ₃ -Ceramic	Al ₂ O ₃ -Ceramic	0.003-0.01	(Al ₂ O ₃)

This figure shows annual linear wear rate of different material combinations as used for cup and head in total hip replacement.



This figure shows the correlation between the in-vivo wear of PE cups and clinical performance

5. Risks and complications

Risks and complications in hip replacement are similar to those associated with all joint replacements. They can include dislocation, loosening, impingement, infection, osteolysis, metal sensitivity, nerve palsy, pain and death.

Dislocation is the most common complication of hip replacement surgery. At surgery the femoral head is taken out of the socket, hip implants are placed and the hip put back into proper position. It takes eight to twelve weeks for the soft tissues injured or cut during surgery to heal. During this period, the hip ball can come out of the socket.

Osteolysis will causes the long term problems with hip replacements. This is the loss of bone caused by the body's reaction to polyethylene wear debris, fine bits of plastic that come off the cup liner over time.

Metal hypersensitivity is a well-established phenomenon and is common. Metal sensitivity and potential dangers of metal particulate debris are getting more and more concerns. Contact with metals can cause immune reactions such as skin hives, eczema, redness and itching. Besides, most hip replacements consist of cobalt and chromium alloys, or titanium. All implants release their constituent ions into the blood. Typically these are excreted in the urine, but in certain individuals the ions can accumulate in the body.

Post operative sciatic nerve palsy is possible complication. Femoral nerve palsy is another but much more rare complication. Both of these will typically resolve over time, but the healing process is slow. Patients with pre-existing nerve injury are at greater risk of experiencing this complication and are also slower to recover.

A few patients who have had a hip replacement suffer chronic pain after the surgery. Groin pain can develop if the tendon that raises the hip (iliopsoas) rubs against the edge of the acetabular cup. Bursitis can develop at the trochanter where a surgical scar crosses the bone, or if the femoral component used pushes the leg out to the side too far. Also some patients can experience pain in cold or damp weather.

The leg can be lengthened or shortened during surgery. Unequal legs are the most common complaint by patients after surgery with over lengthening the most common problem. Sometimes the leg seems long immediately after surgery when in fact both are equal length. An arthritic hip can develop contractures that make the leg behave as if it is short. When these are relieved with replacement surgery and normal motion and function are restored, the body feels that the limb is now longer than it was. If the legs are truly equal, the sense of inequality resolves within a month or two of surgery.

6. Alternatives and variations of hip replacement

Hemiarthroplasty is a surgical procedure which replaces one half of the joint with an artificial surface and leaves the other part in its natural (pre-operative) state. This class of procedure is most commonly performed on the hip after a subcapital (just below the head) fracture the neck of the femur (a hip fracture). The procedure is performed by removing the head of the femur and replacing it with a metal or composite prosthesis. The procedure is recommended only for elderly and frail patients, due to their lower life expectancy and activity level. This is because with the passage of time the prosthesis tends to loosen or to erode the acetabulum.

Hip Resurfacing is an alternative to hip replacement surgery. It is a bone conserving procedure that places a metal cap on the femoral head instead of amputating it. There is no long stem placed down the femur so it is more like a natural hip and may allow patients a return to many activities

Current alternatives also include viscosupplementation, or the injection of artificial lubricants into the joint.

7. Summarize

Currently, the artificial hip replacement is the best way to heal osteoarthritis. The posterior approach gives excellent access to the acetabulum and femur and preserves the hip abductors and thus minimises the risk of abductor dysfunction post operatively. It has the advantage of becoming a more extensile approach if needed. But it also cited a higher dislocation rate. The lateral approach has a lower dislocation risk than the posterior approach, critics note that occasionally the abductor muscles do not heal back on, leading to pain and weakness which is often very difficult to treat. Doing the surgery from an anterior approach seems to lower dislocation rates when small diameter heads are used, but the benefit has not been shown when compared to modern posterior incisions with the use of larger diameter heads. The double incision surgery and minimally invasive surgery seeks to reduce soft tissue damage through reducing the size

of the incision. However, component positioning accuracy and visualization of the bone structures is significantly impaired. This can result in unintended fractures and soft tissue injury.

Now, most hip replacement surgeries today are performed using the standard technique (one 8 to 10 inch cut along the side of the hip), in recent years, some doctors have been using a minimally-invasive technique. In the minimally-invasive approach, doctors make one to two cuts from 2 to 5 inches long. The same procedure is performed through these small cuts as with standard hip replacement surgery.

8. Discussion and future directions

Some believe the future of osteoarthritis treatment is bioengineering, targeting the growth and/or repair of the damaged, arthritic joint. Centeno et al. have reported on the partial regeneration of an arthritic human hip joint using mesenchymal stem cells in one patient. It is yet to be shown that this result will apply to a larger group of patients and result in significant benefits.

Some believe the future of hip replacement surgery is Minimal Invasive Direct Anterior Approach which shorter recovery time with minimal pain.

References:

- [1] <http://en.wikipedia.org/wiki/Osteoarthritis#Causes>
- [2] "What is the Future of Hip Surgery?" featuring Dr. Sculco (ArthritisMD)
<http://www.youtube.com/watch?v=iuB0BsS8oGk>
- [3] <http://www.nlm.nih.gov/medlineplus/hipreplacement.html>
- [4] Tina Nissen¹, Karla Douw² & Søren Overgaard³: Patient reported outcome of hip resurfacing arthroplasty and standard total hip replacement after short term follow up
- [5] N. C. Casartelli, M. Leunig, J. F. Item-Glatthorn, R. Lepers and N. A. Maffiuletti: Hip flexor muscle fatigue in patients with symptomatic femoroacetabular impingement
- [6] Willert HG, Buchhorn GH, Fayyazi A, Flury R, Windler M, Köster G, Lohmann CH.: Metal-on-metal bearings and
- [7] hypersensitivity in patients with artificial hip joints. A clinical and histomorphological study
- [8] G. K. McKee; and J. Watson-Farrar : REPLACEMENT OF ARTHRITIC HIPS BY THE McKEE-FARRAR PROSTHESIS
- [9] CA Engh, JD Bobyn, and AH Glassman: Porous-coated hip replacement. The factors governing bone ingrowth, stress shielding, and clinical results
- [10] Z M Jin, D Dowson, J Fisher :Analysis of fluid film lubrication in artificial hip joint replacements with surfaces of high elastic modulus
- [11] R. Steffen, MRCS, Clinical Research Fellow; K. O'Rourke, FRCS, Consultant Orthopaedic Surgeon; H. S. Gill, DPhil, University Research Lecturer; and D. W. Murray, FRCS, Consultant Orthopaedic Surgeon: The anterolateral approach leads to less disruption of the femoral head-neck blood supply than the posterior approach during hip resurfacing